COVID-19:- A Hypercoagulable State Leading to Pulmonary Embolism When to Thrombolyse and When to Discharge in Emergency Settings

Dr.Azhar Ali[1], Dr.Muhammad Waqas Khan[2], Dr.Mohammad Fawad Khattak[3]

Northampton General Hospital, Northampton[1], Russell Hall Hospital, Sandwell and Dudley[2], Brighton and Sussex University Hospitals, Brighton[3].

Background

- We report a case of bilateral saddle shape large acute pulmonary embolism in a 41 year old gentleman with a one week history of COVID-19, in the hope of increasing understanding of the severity and possible complications of COVID-19 and improving clinical management in acute set up according to the current guidelines.
- Thromboembolism is a common and serious complication of COVID-19. Its incidence increases with the severity of disease. Factors like prolonged bed stay, excessive inflammation and hypoxia may be contributing factors.1 Numerous case reports have emerged detailing pulmonary embolic complications of COVID-19 and there are different hypothesis regarding the pathogenesis of these.

Case Report

- A 41 year old obese gentleman with a one week history of mild COVID-19 pneumonia presented to the emergency department with acute onset of shortness of breath.
- He is normally fit and well with no significant past medical history and takes no medications.
- On arrival he had tachycardia of 113bpm with respiratory rate of 33. Blood pressure was 140/80. His temperature recorded was 38.9.Oxygen saturation was 90% with 5 L of nasal oxygen. Heart sounds were normal but there were bi basal crackles on chest examination.
- ABGs showing type 1 respiratory failure with raised lactate. ECG showing sinus tachycardia with S1Q3T3 pattern typical for pulmonary embolism (figure 1). There were bilateral ground glass opacities and consolidation on CXR (figure 2). His troponin and d dimers were elevated (table 1).
- Bed side echocardiography showed RV strain and (figure 3). Urgent CTPA was arranged which revealed bilateral large saddle shape pulmonary emboli with right heart dilatation .
- Patient was kept in medical HDU under cardiac monitoring and started on therapeutic enoxaparin. On the 2nd day of admission his blood pressure dropped and he became more short of breath. Patient was successfully thrombolysed with IV Alteplase followed by 24 hour heparin.
- Patient was kept in the ward for next 48 hours. He remained oxygen independent and was maintaining his blood pressure. He was successfully discharged home on oral Apixaban with a plan of repeat echocardiography in three month time.

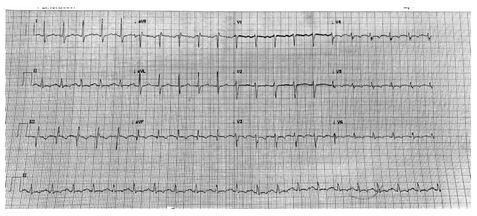

Figure 1: 12 lead ECG on arrival.

D dimers	21601ng/mL
CRP	27mg/L
Troponin	33ng/L
BNP	800pg/ml
Lactate	2.7mmol/L
Creatinine	83 umol/L
WBC	8.6 x 10^9/L
lymphocytes	1.72 x 10^9/L

Table 1. Bloods of the patient taken on arrival

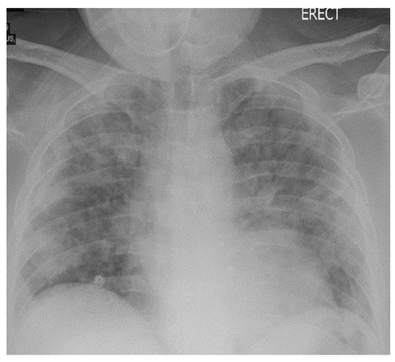

Figure 3: CXR showing bilateral ground glass opacities and consolidation

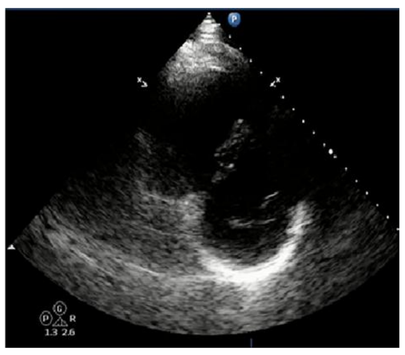

Figure 4: Parasternal short axis on echocardiography showing IVS flattening

Discussion

- COVID-19 a well-known term to everyone now, mainly affecting the respiratory system but other systems are also commonly involved. One of the life threatening feature of COVID-19 is its hypercoagulable state leading to both arterial and venous thromboembolism and its incidence is as high as 31% in ICU patients despite use of standard thromboprophylaxis.2 Autopsy findings revealed deep venous thrombosis up to 58% of patients and pulmonary embolism as a direct cause of death in 33% among them.3
- The exact pathophysiology leading to the thromboembolic nature of the disease is still not clear. It is has been hypothesised that there could be activation of the thrombotic pathway by cytokines as part of the inflammatory process seen in COVID-19. Also, there is damage to the endothelial cells which causes its dysfunction and activation for thrombosis.4 Studies have shown that thromboembolic risk increases with disease severity and hospital stay. Interestingly, baseline D dimers is found very useful to predict risk for future thromboembolism and was found to have negative predictive value up to 98% if less than 1000ng/ml.5
- Management of pulmonary embolism could be challenging. Also, due to its variable presentation it could be difficult to diagnose early. Individual patient should be assess and then managed correctly according to the guidelines. (Figure 5).

- COVID-19 due to its hypercoagulable status could be lethal. Not only one should have knowledge of predictivity of in-hospital thromboembolism risk to initiate appropriate anticoagulant but also early diagnosis of pulmonary embolism is very necessary to decrease mortality. It is very necessary that doctors should have updated knowledge about the current guidelines for pulmonary embolism management in COVID-19 patients so that they can take prompt and confident decision on when to thrombolyse and when to send patients

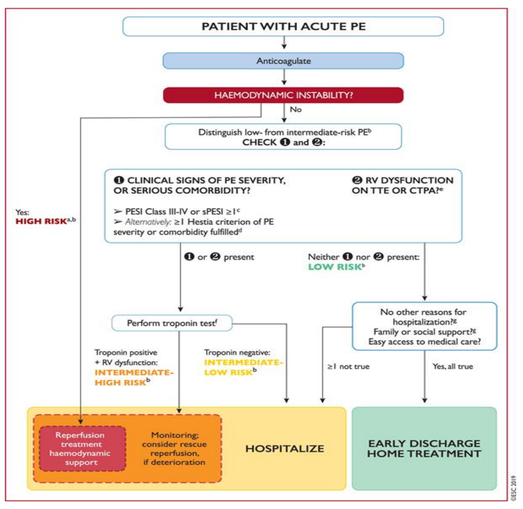

Figure 5: ESC guidelines for management of acute pulmonary embolism

References

1. Klok FA, Kruip MJHA, van der Meer NJM, et al. Incidence of thrombotic complications in critically ill ICU patients with COVID-19. Thrombosis Research. 2020 Apr 10.1016/j.thromres.2020.04.013.
2. Klok, F.A., Kruip, M.J.H.A. and Meer, N.J.M., 2020. van der, Arbous, MS, Gommers, D. a. MPJ, Kant.
3. Wichmann, D. and Sperhake, J.P., 2020. Lütgehetmann Met al. Autopsy findings and venous thromboembolism in patients with COVID-19: a prospective cohort study Ann Intern Med2020. Doi, 10, pp.M20-2003.
4. Middeldorp, S, Coppens, M, van Haaps, TF, et al. Incidence of venous thromboembolism in hospitalized patients with COVID-19. J Thromb Haemost. 2020; 18: 1995– 2002. https://doi.org/10.1111/jth.14888
5. Artifoni, M., Danic, G., Gautier, G., Gicquel, P., Boutoille, D., Raffi, F., Néel, A. and Lecomte, R., 2020. Systematic assessment of venous thromboembolism in COVID-19 patients receiving thromboprophylaxis: incidence and role of D-dimer as predictive factors. Journal of Thrombosis and Thrombolysis, p.1.